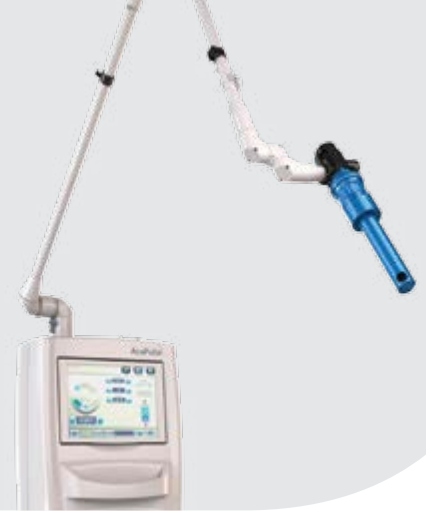

# The use of CO<sub>2</sub> laser for patients with Lichen sclerosus

Dr. Christina Kuhler-Obbarius, Elisabeth Kunkel, Dr. Matthias Theden-Schow,  
Hamburg, Germany



Our clinical center located in Hamburg includes eight gynecologists that specialize in treatment of genital skin problems. We have been working with CO<sub>2</sub> lasers for the past twenty years for incisions or aesthetic procedures and have treated a variety of gynecological problems. The CO<sub>2</sub> laser is used in our clinic to treat patients with human papillomavirus-associated dysplasia, genital or vulvar diseases, condiloma, vaginal atrophy, stress urinary incontinence, vestibulodynia and Lichen sclerosus.

Working with the AcuPulse, our personal impression is that this CO<sub>2</sub> laser is very powerful and more importantly, a very precise laser that can give us the best results in less time. From the patient's perspective, we would say that the treatment with CO<sub>2</sub> laser is less aggressive, more convenient and the recovery is faster since no hospitalization is needed following the procedure. We like the fact that we can offer the treatment to a variety of patients with various conditions such as postmenopausal vulvovaginal atrophy, vaginal dryness in breast feeding women or urogenital diseases.

We first became aware of the possibility to treat Lichen Sclerosus patients with fractional CO<sub>2</sub> laser after reading about it and exploring it in the literature. Patient's requests to find a solution for their bothering symptoms drove us to explore this advanced technology. We had the perception that CO<sub>2</sub> laser would be effective for Lichen Sclerosus as it is for vulvovaginal atrophy since the histology of Lichen Sclerosus is similar to the one seen in atrophic tissue. (See figure 1)

We have treated more than twenty Lichen Sclerosus patients with the FemTouch handpiece and there are many patients that are waiting to be treated. We get to see patients from all over Germany coming from afar to get the treatment since we are considered to be an expert clinic that uses an advanced technology for Lichen Sclerosus patients.

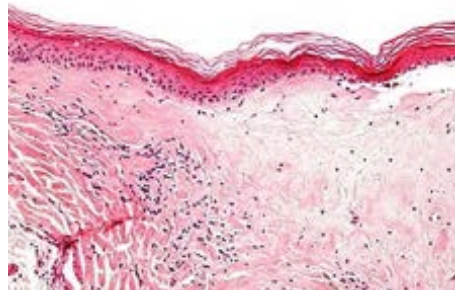


Figure 1: Lichen sclerosus showing the characteristic subepithelial sclerosis. H&E stain

## What is Lichen Sclerosus?

Vulvar Lichen Sclerosus is a chronic inflammatory dermatosis that causes substantial discomfort (intractable itching, soreness, constipation and dyspareunia) and morbidity (introital narrowing, burying of the clitoris, and atrophy labia minora).

The localization is around the entire vulva and it may extend to the area of the anus. Diagnosis is based mostly on clinical observation, however, in some cases in which the clinical diagnosis is uncertain, the first line treatment fails or malignancy is suspected, a confirmatory biopsy is warranted<sup>1</sup>. Symptoms include itching, especially at night, shrinking of the skin and synechia that causes dyspareunia. The prepuce of the clitoris often shrinks, as a result of the chronic inflammation, leading to covering (“hooding”) of the clitoris. While some cases present with stenosis of the vaginal introitus, the vagina is rarely affected<sup>2</sup>.

The etiology of Lichen Sclerosus is yet unknown. Sometimes, it can begin following a trauma or irritation of the skin. The first symptoms to be noted and main complaints are itching. The intensity of the itching may cause patients to scratch the skin, even unconsciously at night to the degree of causing bleeding, that provides temporary relief of the itching. Most patients are treated with local potent to very potent corticosteroids. Usually starting with once a day application of corticosteroid cream for 6-12 weeks. Thereafter, maintenance therapy of two times a week is recommended. The aim of treatment is improvement of symptoms (shown in 75-95% of patients) after 3 months. Early detection and consistent treatment have been shown to be positive factors in treatment success, however, scarring is considered to be irreversible<sup>1</sup>. Lichen sclerosus is associated with a higher incidence of squamous cell carcinoma (SCC) of the vulva. This may also be caused by the prolonged therapy with high potential cortisone that cause local immune-suppression<sup>3</sup>.

Laser therapy has shown a lot of promise in relieving symptoms of Lichen Sclerosus<sup>4,5</sup> and treatment for Lichen Sclerosus with CO<sub>2</sub>-Laser may reduce the need for corticosteroids. A case series in 7 patients has shown success in relieving symptoms and 6 of the patients were symptom free for up to 37 months of follow-up<sup>6</sup>. A later paper reported on 2 women who did not respond to treatment with propionate 0.05% and following CO<sub>2</sub> treatment exhibited normal re-epithelialization of the vulval tissue and prolonged relief of symptoms (3 years of follow-up)<sup>7</sup>. Most recently, Lee and colleagues have reported on 4 women whose lichen sclerosus was severe, hyperkeratotic and refractory to super-potent topical corticosteroids. Following CO<sub>2</sub> laser treatment, remission was achieved and was later maintained with the use of corticosteroids.

## When would you consider treatment with CO<sub>2</sub> vaginal and external treatment?

We would suggest patients to consider FemTouch treatment when no relief of symptoms is gained by the topical creams. Based on our experience, every patient with Lichen Sclerosus can benefit from FemTouch treatment.

## Patients that should be included:

In our opinion, the treatment with fractional CO<sub>2</sub>-Laser may be recommended for all patients that suffer from Lichen sclerosus (following consultations and at the physician discretion). Fractional CO<sub>2</sub> laser therapy may provide relief of symptoms such as sensation of dryness, itching, irritation and discomfort.

## Patient that should be excluded from treatment with CO<sub>2</sub> lasers:

We would not provide fractional CO<sub>2</sub> laser treatment in cases in which there is active bacterial or fungal infection, pre-cancer dysplasia or in any case that there is a suspected malignancy. It is important that any signs of vulvar intraepithelial neoplasia or carcinoma are excluded. If there are signs of erosion that might be a VIN (Vulval intra-epithelial neoplasia) or carcinoma, then a biopsy of this area should be done.

## Pretreatment instructions:

For external treatment, we apply a topical anesthetic cream (Pliaglis, lidocaine 7% and tetracaine 7%) 20 minutes before the procedure. It is important to remove the cream before treatment and to dry the area with a sterile gauze in order to ensure that the CO<sub>2</sub> Laser can effectively penetrate into the epidermis and will not be absorbed by the cream.

## Treatment settings:

### External treatment (AcuScan120):

Energy: 10 mJ.

Density: 10%.

In case that it is not comfortable to patient reduce energy to 7.5 mJ.



### Internal treatment (FemTouch):

Energy: 7.5 - 10 mJ.

Density: 10%.

If a subject suffers from vaginal symptoms in addition to Lichen Sclerosus, we perform a combined treatment with the FemTouch tip and the AcuScan120.



## How many treatments are required?

Usually at least three treatment sessions with an interval of six weeks are recommended. Based on our experience, the healing of the skin is longer in patients with Lichen Sclerosus, therefore, the interval should be a little longer than with patient that suffer from vaginal atrophy (4 weeks).

The treatment should be done for all skin areas from the introits, over the labia minora and the labia majora where signs of the lichen are shown. (See figure 2)

It depends also on the thickness of the skin. If there is still a hyperkeratosis, then we can use more energy. If there is thinner skin following treatment with cortisone, then we use lower energy.

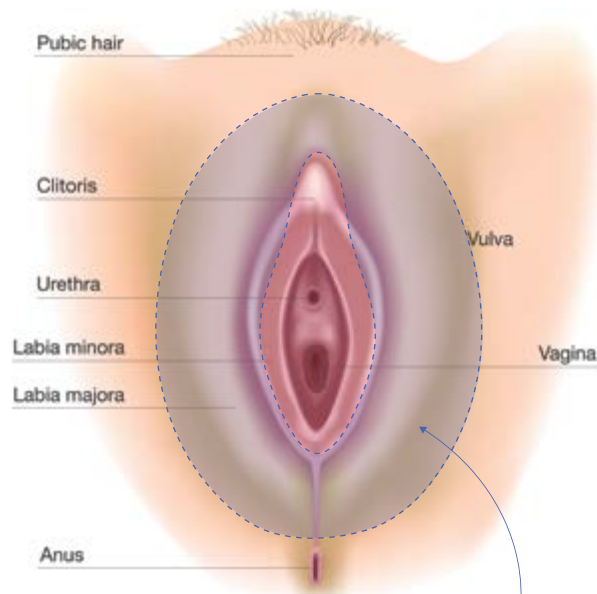


Figure 2: treatment area  
Treatment area marked in blue

## Post procedure instructions:

The post treatment instructions are to avoid having hot baths or sexual intercourse in the following 72 hours.

In addition, we do not recommend to use cortisone for one or two weeks following the procedure. Up to two days after the treatment, the patient may note that the skin in the treated area is peeling.

It has been noted that following laser treatment, patients do not need cortisone, but in some cases after the first treatments when a sensation of itching still exists, it is recommended to apply cortisone.

In any case, a Lichen Sclerosus patient has to come twice a year for follow-up evaluation of the disease.

---

## Case study:

Patient age 59, had Lichen Sclerosus since she was young, medical history includes, past two cesarean deliveries, Hashimoto's disease and ulcerative colitis. She was treated with cortisone and it provided some relief. Last menses was two years ago. Since then, she has been suffering from vaginal atrophy in addition to Lichen Sclerosus.

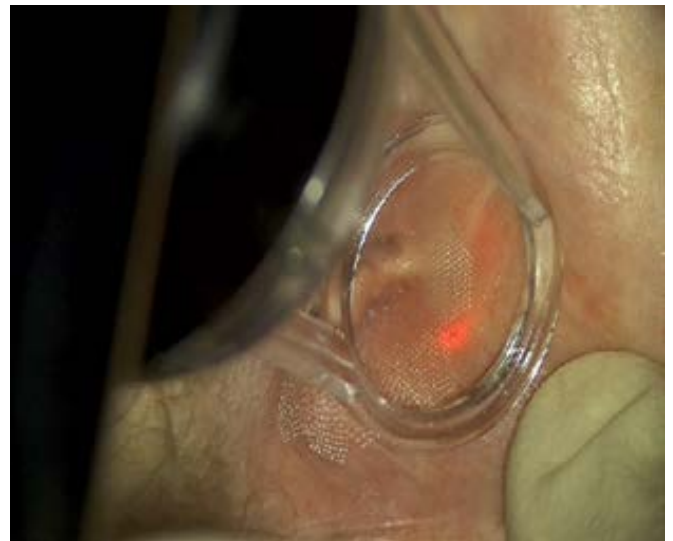
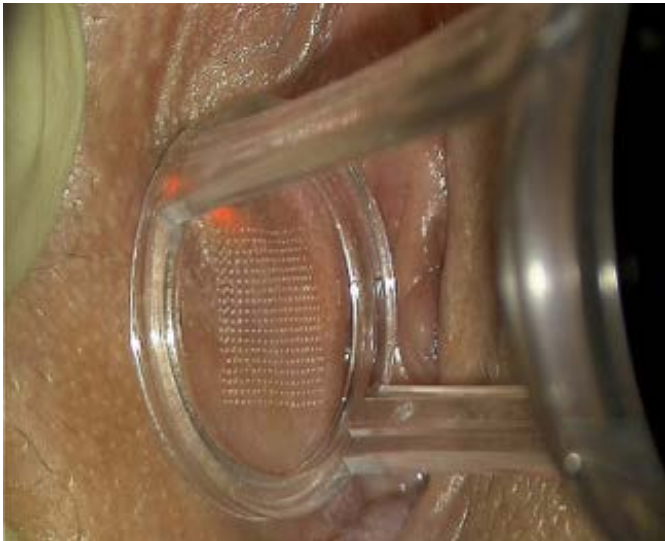**Treatments:** Internal FemTouch treatment and external treatment were provided (picture 1).

**The setting used were:**

**External treatment (AcuScan120, Deep mode):** Energy: 10, Density: 10%.

**Internal treatment (FemTouch):** Energy: 10, Density: 10%.

Second treatment was done 8 weeks apart, energy 7.5 mJ and density 10%. Following treatment the patient noted that the skin was peeling and was sensitive for touch. Two weeks later following second treatment (picture 2) patient was satisfied, feeling relief of symptoms and the appearance look younger and pinkish.

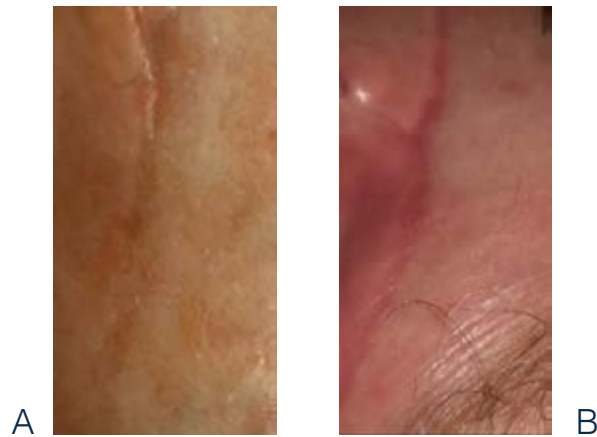


PICTURE 1

External treatment of the labia minora  
with AcuScan120

## PICTURE 2

Effect of the treatment seen two weeks following second treatment (B) compared to baseline (A) Improvement in skin coloration and appearance is apparent.



## Warnings and risks

CO<sub>2</sub> lasers are intended solely for use by physicians trained in the use of the Carbon Dioxide laser (10.6 μm) wavelength. Incorrect treatment settings or misuse of the technology can present risk of serious injury to patient and operating personnel. Risks that may be associated with any CO<sub>2</sub> laser procedure may include change of pigmentation, infection, erythema, skin induration or scarring.

Read and understand the CO<sub>2</sub> systems and accessories operator manuals for a complete list of intended use, contraindications and risks. The use of Lumenis® CO<sub>2</sub> laser is contraindicated where a patient has taken Accutane (Isotretinoin) within the past 6-12 months, has a history of keloid formation and demonstrate excessive or unusually prolonged erythema.

## References

1. Kirtschig G, Becker K, Günthert A, et al. Evidence-based (S3) Guideline on (anogenital) Lichen sclerosus. J Eur Acad Dermatol Venereol JEADV. 2015;29(10):e1-43. doi:10.1111/jdv.13136.
2. Marnach ML, Torgerson RR. Vulvovaginal Issues in Mature Women. Mayo Clin Proc. 2017;92(3):449-454. doi:10.1016/j.mayocp.2016.10.031.
3. Wang S-H, Chi C-C, Wong YW, Salim A, Manek S, Wojnarowska F. Genital verrucous carcinoma is associated with lichen sclerosus: a retrospective study and review of the literature. J Eur Acad Dermatol Venereol JEADV. 2010;24(7):815-819. doi:10.1111/j.1468-3083.2009.03531.x.
4. Baggish MS. Fractional CO<sub>2</sub> laser treatment for vaginal atrophy and vulvar lichen sclerosus. J Gynecol Surg. 2016;32(6):309-317.
5. Lee A, Lim A, Fischer G. Fractional carbon dioxide laser in recalcitrant vulval lichen sclerosus. Australas J Dermatol. 2016;57(1):39-43. doi:10.1111/ajd.12305.
6. Stuart GC, Nation JG, Malliah VS, Robertson DI. Laser therapy of vulvar lichen sclerosus et atrophicus. Can J Surg J Can Chir. 1991;34(5):469-470.
7. Peterson CM, Lane JE, Ratz JL. Successful carbon dioxide laser therapy for refractory anogenital lichen sclerosus. Dermatol Surg Off Publ Am Soc Dermatol Surg Al. 2004;30(8):1148-1151. doi:10.1111/j.1524-4725.2004.30343.x.

